


I. Percutaneous Transvenous Mitral Commissurotomy : PTMC (Mitral Valvuloplasty)

- 1) Inoue K, Owaki T, Nakamura T, Kitamura F, Miyamoto N: Clinical application of transvenous mitral commissurotomy by a new balloon catheter. *J.Thorac. Cardiovasc. Surg.* 87(3):394-402, 1984.
- 2) Inoue K, Nakamura T, Kitamura F, Miyamoto N: Transvenous mitral commissurotomy by a new balloon catheter. *Eur. Heart J.5(Suppl 1): 111, 1984(abst.)*
- 3) Inoue K, Owaki T, Nakamura T, Kitamura F, Miyamoto N, Chen CR: Transvenous mitral commissurotomy: Long term Follow-up and recent modification. *Circulation 74(Suppl II): II-208, 1986(abst.)*
- 4) Inoue K, Hung JS, Chen CR, Cheng TO: Mitral stenosis: Inoue Balloon Catheter technique. *Percutaneous Balloon Valvuloplasty*, ed, by Cheng TO, Igakushoin, 237-279, 1992.
- 5) Inoue K, Hung JS: Percutaneous transvenous mitral commissurotomy (PTMC): The far east experience. *Textbook of Interventional Cardiology*, ed. by E.J. Topol, W.B. Saunders Company, 887-899, 1990.
- 6) Inoue K, Chen CR, Hung JS: Percutaneous transvenous mitral commissurotomy guided and assessed by echocardiography. *Echocardiography in Cardiac Interventions*, ed. by Cikes I, Kluwer Academic Publishers, 67-76, 1989.
- 7) Feldman T, Carroll JD: Valve deformity and balloon mechanics in percutaneous transvenous mitral commissurotomy. *Am. Heart J.121(6): 1628-1633, 1991.*
- 8) Tsai RC, Yamaji T, Ishibashi M, Takaku F, Fu M, Cherng WJ, Inoue K, Hung JS: Atrial natriuretic peptide and vasopressin during percutaneous transvenous mitral valvuloplasty and relation to renin-angiotensin-aldosterone system and renal function. *Am. J.Cardiol.* 65:882-886, 1990.
- 9) Hung JS, Fu M, Cherng WJ, Inoue K, Tsai RC, Ishibashi M, Yamaji T: Rapid fall in elevated plasma atrial natriuretic peptide levels after successful catheter balloon valvuloplasty of mitral stenosis. *Am. Heart J.117(2):381-385, 1989.*
- 10) Nobuyoshi M, Hamasaki N, Kimura T, Nosaka H, Yokoi H, Yasumoto H, Horiuchi H, Nakashima H, Shindo T, Mori T, Miyamoto A, Inoue K: Indications, complications, and short-term clinical outcome of percutaneous transvenous mitral commissurotomy. *Circulation 80(4): 782-792, 1989.*
- 11) Chen CR, Lo ZX, Huang ZD, Inoue K, Cheng TO: Percutaneous transseptal balloon, mitral valvuloplasty: The Chinese experience in 30 patients. *Am. Heart J.115(5):937-947, 1988.*
- 12) Matsuura Y, Fukunaga S, Ishihara H, Hamanaka Y, Sueda T, Kajiyama G, Matsuura H, Okamoto M, Inoue K: Mechanics of percutaneous balloon valvotomy for mitral valvular stenosis. *Heart Vessels 4: 179-183, 1988.*
- 13) Orihashi K, Matsuura Y, Ishihara H, Hamanaka Y, Kawae Y, Sueda T, Kanehiro K, Nomimura T, Okamoto M, Tsuchioka Y, Inoue K: Transvenous mitral commissurotomy examined with transesophageal echocardiography. *Heart Vessels 3:209-213, 1987.*
- 14) Macaya C, Banuelos C, Fernández-Ortiz A, Rodrigo JL, Cortés J, Iniguez A, Alfonso F, Inoue K, Zarco P: Valvulotomia mitral percutánea con la técnica de Inoue. *Rev. Esp. Cardiol.* 43:371-376, 1990.
- 15) Hung JS: Mitral stenosis with left atrial thrombi: Inoue Balloon Catheter technique. *Percutaneous Balloon Valvuloplasty*, ed, by Cheng TO, Igakushoin, 280-293, 1992.
- 16) Hung JS, Chern MS, Wu JJ, Fu M, Yeh KH, Wu YC, Cherng WJ, Chua S, Lee CB: Short and long-term results of catheter balloon percutaneous transvenous mitral commissurotomy. *Am. J.Cardiol.* 67:854-862, 1991.
- 17) Hung JS, Fu M, Yeh SJ, Lin FC, Cherng WJ, Yeh KH, Wu YC, Wu D: Hemodynamic and clinical efficacies of catheter balloon percutaneous transvenous mitral commissurotomy: Experience of 100 patients with rheumatic mitral stenosis. *J.Formosan. Med. Assoc.* 89(3):182-189, 1990.
- 18) Hung JS, Lin FC, Chiang CW: Successful percutaneous transvenous catheter balloon mitral commissurotomy after warfarin therapy and resolution of left atrial thrombus. *Am. J.Cardiol.* 64:126-128, 1989.
- 19) Tsai LM, Hung JS, Chen JH, Lin LJ, Fu M: Resolution of left atrial appendage thrombus in mitral stenosis after warfarin therapy. *Am. Heart J.121(4)part 1:1232-1234, 1991.*
- 20) Chen CR, Hu SW, Chen JY, Zhou YL, Mei J, Cheng TO: Percutaneous mitral valvuloplasty with a single rubber-nylon balloon (Inoue-Balloon): Long-term results in 71 patients. *Am. Heart J.120(3):561-568, 1990.*
- 21) Chen CR, Huang ZD, Lo ZX, Cheng TO: Comparison of single rubber-nylon balloon and double polyethylene balloon valvuloplasty in 94 patients with rheumatic mitral stenosis. *Am. Heart J.119(1)102-111,1990.*
- 22) Babic UU: Inoue-Technique, Percutaneous: Mitral valvuloplasty, LA-AO, LV-AO bypass, PDA closure with a new device. *A workbook*, 68-97, 1990.
- 23) Nagata S, Ishikura F, Yamabe T, Akaike M, Kimura K, Miyatake K: Balloon diameter of the Inoue Balloon Catheter during percutaneous transvenous mitral commissurotomy: Clinical and experimental study. *Cathet. Cardiovasc. Diagn.* 23:14-19, 1991.
- 24) Nakatani S, Nagata S, Beppu S, Ishikura F, Tamai J, Yamagishi M, Ohmori F, Kimura K, Takamiya M, Miyatake K: Acute reduction of mitral valve area after percutaneous balloon mitral valvuloplasty: Assessment with Doppler continuity equation method. *Am. Heart J.121(3)part 1: 770-775, 1991.*
- 25) Ishikura F, Nagata S, Yasuda S, Yamashita N, Miyatake K: Residual atrial septal perforation after percutaneous transvenous mitral commissurotomy with Inoue Balloon Catheter. *Am. Heart J.120(4):873-878,1990.*
- 26) Ishikura F, Nagata S, Hirata Y, Kimura K, Nakatani S, Tamai J, Yamagishi M, Ohmori F, Beppu S, Takamiya M, Miyatake K, Nimura Y: Rapid reduction of plasma atrial natriuretic peptide levels during percutaneous transvenous mitral commissurotomy in patients with mitral stenosis. *Circulation 79(1):47-50, 1989.*
- 27) Yoshioka T, Nakanishi N, Okubo S, Kunieda T, Ishikura F, Nagata S: Improvement in pulmonary function in mitral stenosis after percutaneous transvenous mitral commissurotomy. *Chest 98(2):290-294, 1990.*
- 28) Nishimura RA, Holmes DR, Jr., Reeder GS: Efficacy of percutaneous mitral balloon valvuloplasty with the Inoue Balloon. *Mayo-Clin. Proc.* 66:276-282, 1991.
- 29) Fields CD, Slovenkai GA, Isner JM: Atrial septal defect resulting from mitral balloon valvuloplasty: Relation of defect morphology to transseptal balloon catheter delivery. *Am. Heart J.119(3)part 1: 568-576, 1990.*
- 30) Benit E, Rocha P, Geest H, Werf FV: Successful mitral valvuloplasty using the Inoue Balloon in a patient with mitral stenosis associated with subvalvular fibrosis and reduced left ventricular inflow cavity: A case report. *Cathet. Cardiovasc. Diagn.* 22:35-38, 1991.
- 31) Tanimura H, Inden M, Konishi T, Nakano T: Hemodynamic improvement after percutaneous transseptal mitral commissurotomy (PTMC) in patients with mitral stenosis. *Mie Med. J.39(3):333-338, 1989.*
- 32) "Hourglass" balloon system hastens mitral valvotomy. *Cardio, March, 114 A, 1991.*
- 33) Inoue K: Percutaneous transvenous mitral commissurotomy using the Inoue balloon. *Eur Heart J. 12(Suppl B): 99-108, 1991*
- 34) Bassand JP, Schiele F, Bernard Y, Anguenot T, Payet M, Ba SA, Daspert JP, Maurat JP: The double-balloon and Inoue techniques in percutaneous mitral valvuloplasty: Comparative results in a series of 232 cases. *J.A.C.C.* 18(4): 982-989, 1991
- 35) Benit E, Geest HD, Deneff B, Werf FV: Early and 3 months follow-up results in 22 adult patients undergoing percutaneous transvenous mitral valvuloplasty. *Acta Cardiologica XLV: 425-440, 1990*
- 36) Benit E, Vrolix M, Glazier JJ, Sionis D, Werf FV: Percutaneous transvenous mitral valvuloplasty, percutaneous transluminal coronary angioplasty, and coronary thrombolysis applied successfully to one patient. *J. Intervent. Cardiol.* 4(3), 1991
- 37) Feldman T, Carroll JD: Percutaneous transvenous balloon mitral commissurotomy: When? For whom? *J.Critical Illness 6(10): 1009-1024*
- 38) Bernard Y, Bassand JP, Schiele F, Anguenot T, Payet M, Abdou S, Maurat JP: Percutaneous mitral valvulotomy in non-optimal candidates. *Eur. Heart J. 12(Suppl B): 90-94, 1991*
- 39) Patel JJ, Shama D, Mitha AS, Blyth D, Hassen F, LeRoux BT, Chetty S: Balloon valvuloplasty versus closed commissurotomy for pliable mitral stenosis: A prospective hemodynamic study. *J.A.C.C.* 18(5): 1318-1322, 1991.
- 40) Shaw TRD, Elder AT, Flapan AD, Essop AR: Mitral balloon valvuloplasty for patients aged over 70 years: An alternative to surgical treatment. *Age and Ageing 20:299-303, 1991.*
- 41) Feldman T, Carroll JD, Isner JM, Chisholm RJ, Holmes DR, Massumi A, Pichard AD, Herrmann HC, Stertzler SH, O'Neill WW, Dorros G, Sundram P, Bashore TM, Ramaswamy K, Jones LS, Inoue K: Effect of valve deformity on results and mitral regurgitation after Inoue Balloon commissurotomy. *Circulation 85(1): 180-187, 1992.*
- 42) Rihal CS, Nishimura RA, Holmes DR: Percutaneous balloon mitral valvuloplasty: The learning curve. *Am. Heart J. 122(6): 1750-1756, 1991.*

# INOUE-BALLOON



For Percutaneous Transvenous Mitral Commissurotomy (PTMC)

**'TORAY'**

Exporter :  
Toray Medical Co., Ltd.  
8-1, Mihama 1-chome, Urayasu,  
Chiba 279-8555, Japan  
Telephone: +81 (47) 700-7549  
Telefax: +81 (47) 700-7558

Manufacturer :  
Toray Industries, Inc.  
1-1, Nihonbashi-Muromachi, 2-chome, Chuo-ku,  
Tokyo 103-8666, Japan

Representatives : CE 0123

Toray International Italy S.r.l.  
Via Mecenate 86, 20138 Milan, Italy  
Telephone: +39 (02) 58039133

Toray International America Inc.  
140 Cypress Station Drive, Suite 210, Houston,  
TX 77090, U.S.A.  
Telephone: +1 (281) 587-2299

Toray International Singapore Pte. Ltd.  
111 Somerset Road #14-01, Singapore 238164  
Telephone: +65 6505-3198

**'TORAY'**

Toray Medical Co., Ltd.

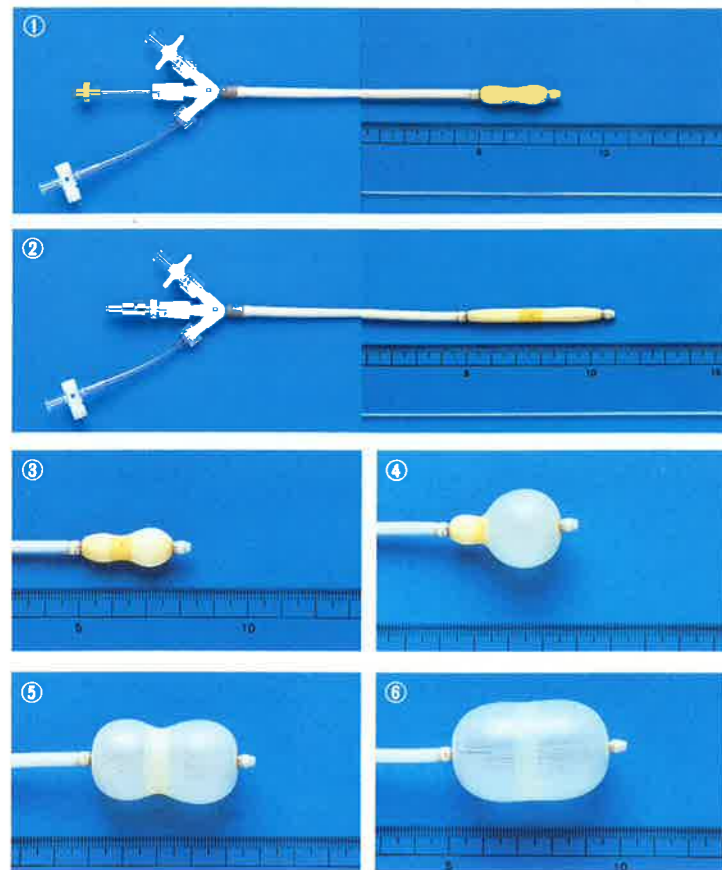


# INOUE-BALLOON Permits Safe Percutaneous Transvenous Mitral Commissurotomy (PTMC)



The first balloon catheter for the treatment of mitral stenosis has the following simple operative procedures :

### Simple Operative Procedure:



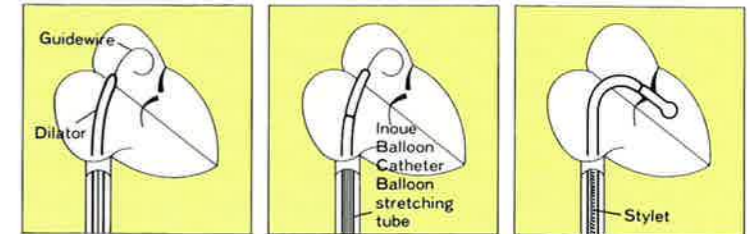
- ① Original shape.
- ② Introduce the balloon stretching tube to slenderize and elongate the balloon.
- ③ Inflate the distal portion of the balloon slightly (10-15mm) with dilute contrast media.
- ④-⑥ The balloon inflates in three stages.

### Advantages:

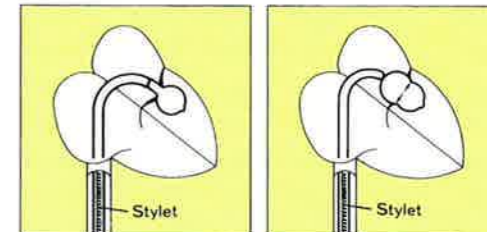
- (1) A single balloon catheter provides a sufficient expansion range to assure a simple as well as safe procedure.
  - (2) The low profile of the stretched balloon facilitates percutaneous introduction through the femoral vein. This technique prevents the development of atrial septal defect (ASD). (photo-②)
  - (3) Changing the shape of the balloon with the filling volume simplifies placing the catheter at the site of stenosis (photo-③). The volume controlled hour-glass shape of the balloon assures proper positioning at the stenosis, prevents migration of the catheter and provides optimal dilation (photo-④,⑤,⑥).
  - (4) The range of each balloon size is controlled by the volume of dilute contrast medium. (See table)
- | Cat. No.        | Balloon diameter range |
|-----------------|------------------------|
| PTMC-30, IMS-30 | 26mm~30mm              |
| PTMC-28, IMS-28 | 24mm~28mm              |
| PTMC-26, IMS-26 | 22mm~26mm              |
| PTMC-24, IMS-24 | 20mm~24mm              |
| PTMC-22, IMS-22 | 20mm~22mm              |
| PTMC-20, IMS-20 | 18mm~20mm              |
- (5) The unique balloon construction exhibits dynamic inflation properties sufficient for valvular expansion. Rapid inflation/deflation cycle (5sec.) quickly returns valve to normal function.
  - (6) This treatment (PTMC) is performed without thoracotomy with the following special features:
    - Short procedure time
    - Short hospital stay
    - Can be indicated for the debilitated elderly, patients with renal insufficiency; pregnant women; patients with poor surgical risk.

### Indication and Directions for Use:

- Mitral valve stenosis
- Directions for Use (Summary)



- ① After inserting the guidewire into the left atrium, expand atrial septal puncture with the dilator.
- ② Insert the balloon catheter with the balloon stretching tube incorporated.
- ③ Place the balloon at the valvular opening using the stylet.




- ④ Inflate the distal portion of the balloon to place it at the valvular opening.
- ⑤ Inflate the entire balloon to expand the opening of the valve.

- Note 1: For details, read package insert (in the kit box).  
 Note 2: This procedure should be carried out only by physicians trained and qualified in PTMC techniques.  
 Note 3: Use of this procedure is recommended only in facilities where cardiac surgery can be performed within a reasonable period of time.

### Set Contents

Description	Use
① Inoue Balloon Catheter	Dilation of mitral valve
② Balloon stretching tube	Elongation of balloon
③ Dilator	Dilation of insertion areas
④ Guidewire	Guiding the balloon catheter and dilator
⑤ Stylet (spring)	Directing balloon to mitral valve
⑥ Syringe	Inflation of balloon
⑦ Ruler	Measurement of balloon diameter



### SPECIFICATION

#### 1 INOUE-BALLOON

Cat. No.	Balloon Diameter (Max)	Catheter Size		Patient Height
		Outer Diameter	Length	
PTMC-30, IMS-30	30mm	12Fr.	70cm	> 180cm
PTMC-28, IMS-28	28mm	12Fr.	70cm	> 160cm
PTMC-26, IMS-26	26mm	12Fr.	70cm	> 147cm
PTMC-24, IMS-24	24mm	12Fr.	70cm	≤ 147cm
PTMC-22, IMS-22	22mm	12Fr.	70cm	≤ 147cm
PTMC-20, IMS-20	20mm	12Fr.	70cm	≤ 147cm

※IMS-30, IMS-28, IMS-26, IMS-24, IMS-22, IMS-20, contains balloon catheter and syringe only.  
 ● Package: 1 Set/case ● EOG sterile

#### Individually supplied as follows

Cat. No.	Description	Size	
		Outer Diameter	Length
KMS-1	Balloon stretching tube	1.2mm	80cm
DMS-1	Dilator	14Fr.	70cm
GMS-1	Guidewire	.025"	175cm
SMS-1	Stylet	.038"	80cm
NMS-1	Ruler	—	—

● Package: 2 Units/case ● EOG sterile